

Autologous pericardium as patch material in the high pressure-system – report of a case of subsequent development of an aneurysm and review of the literature

Muhammed Kurt¹, Arno Krian², Jens Litmathe¹

¹Department of Thoracic and Cardiovascular Surgery, Heinrich Heine University, Düsseldorf, Germany

²Department of Thoracic and Cardiovascular Surgery, Heart Centre Duisburg, Germany

Submitted: 23 July 2006

Accepted: 11 September 2006

Arch Med Sci 2006; 2, 4: 286-288

Copyright © Termedia & Banach

Corresponding author:

Jens Litmathe MD, PhD
Department of Thoracic
and Cardiovascular Surgery
Heinrich Heine University Hospital
Moorenstrasse 5
D-40225 Düsseldorf
Germany
Phone: +49 211 811 83 31
Fax: +49 211 811 83 33
E-mail:
litmathe@med.uni-duesseldorf.de

Abstract

We report the case of a young patient who underwent renewed aortic valve replacement, after open blasting of the aortic valve and subsequent valve replacement with enlargement of the ascending thoracic aorta using an autologous pericardium patch had already taken place. In the context of the former enlargement of the aortic root the development of an aneurysm was seen and was resected in the same setting without any difficulties. Particular items with special regard to the postoperative course, including neurological symptoms due to prolonged operation and cross-clamp-times, are delineated in the following report and compared to the current findings from the literature.

Key words: aneurysm, pericardium patch, aortic valve replacement.

Introduction

The operative strategy of elimination of tissue defects or the correction of complex congenital malformations is various [1-5]. Within such procedures autologous material is frequently used, e.g. autologous pericardium in the form of a patch. Mostly in the long-term follow-up of those patients the development of an aneurysm can be observed in the area of the patch [6]. The risk of a rupture in this area is at least the same as it is in presence of an aneurysm verum [7].

Case report

We report on a 46-year-old female patient, who already had undergone open blasting of the aortic valve in 1967 due to valvular stenosis.

Nine years later prosthetic valve replacement was required because of the recurrence of both valvular and subvalvular stenosis. For the implantation of a Björk-Shiley® prosthesis the right coronary cusp had to be separated from the aortic one and the aortic valve ring, which was extremely tight, had to be incised.

After the incision in this area there was a gap in the aortic wall which was repaired using an autologous pericardium patch.

Concerning her current anamnesis the patient reported at admission to our institution typical symptoms of dyspnoea in exercise according to NYHA III.

Table I. Review from the literature concerning aneurysm development after autologous patch repair in open-heart surgery. VSD = ventricular septal defect, RVOT – right ventricular outflow tract

Author, year	Study – population	Incidence of aneurysm	Follow-up
Butera, 2001 [10]	case report of a 14-day-old infant undergoing VSD closure	100%	two months
Bennink, 2001 [11]	case report of a newborn undergoing VSD closure; aneurysm causes RVOT obstruction	100%	two months
Napoleone, 2003 [12]	195 patients undergoing correction of aortic coarctation	6.6%	6 months-18 years
Schoof, 1998 [13]	102 children undergoing VSD closure	2.9%	1 day-50 weeks
Al-Hroob, 2003 [15]	19 patients undergoing correction of aortic coarctation	63%	3 months-17.5 years
Bromberg, 1989 [16]	29 children undergoing correction of aortic coarctation	24%	1-19 years
Ala-Kulju, 1989 [17]	67 patients undergoing correction of aortic coarctation	32.8%	9-16 years

The physical examination evaluated a distinct systolic ejection murmur in the right second intercostal space, although without a clear diastolic flow pattern.

The angiography that had already been carried out in the admitting hospital showed a severe dysfunction of the prosthesis with a mean pressure gradient of 68 mmHg.

Apart from the moderately restricted left ventricular function a slight mitral valve insufficiency could be observed. The bulbous angiography showed a clear, partially circumscribed ectasia in the area of the sinus of Valsalva (Figure 1).

Thus, the indication for re-do surgery was ensured. The corresponding procedure was carried out under routine circumstances. The intraoperative finding presented itself to be congruent with the preoperative evaluated angiographic status. The aneurysm in the area of the pericardium patch was resected and the patient underwent renewed aortic valve replacement.

The postoperative course, however, was not completely uneventful: Although stable haemodynamics could be guaranteed at any time without the support of catecholamines, postoperative mechanical ventilation was necessary for eight days. Besides that, a left-sided motoric dysfunction was proved as hemiparesis. Cranial computer tomography (CCT) showed ischaemic changes in the area of the right-sided medial cerebral artery. Apart from this, a diffuse but slight brain swelling could be. The clinical symptoms were quickly retrograde so that five days after the extubation the patient could be discharged to the intensive care unit of the admitting hospital for further maintenance.

After another stay of approximately four weeks in hospital there, the patient presented herself in an almost physiologic neurological status without cognitive dysfunction and was considered for rehabilitation.

Discussion

After the quite early establishment of open heart surgery the correction of congenital and acquired tissue defects has begun [8].

The underlying technical procedures are various and in some instances difficult. The literature frequently reports on the use of both synthetic patches and autologous material, such as pericardium [3, 14].

The use of autologous material is comparably difficult: The pericardium patch is used in a wide range, from the post-infarctial VSD correction to the intracardiac correction of the Tetralogy of Fallot [9].

The complications in those cases, which, however, mainly impair the patients' outcomes, are represented by the development of aneurysms in the area of the employed patches.

According to this case, the literature provides different incidences and refers to a high correlation to the current patient. Some authors even describe

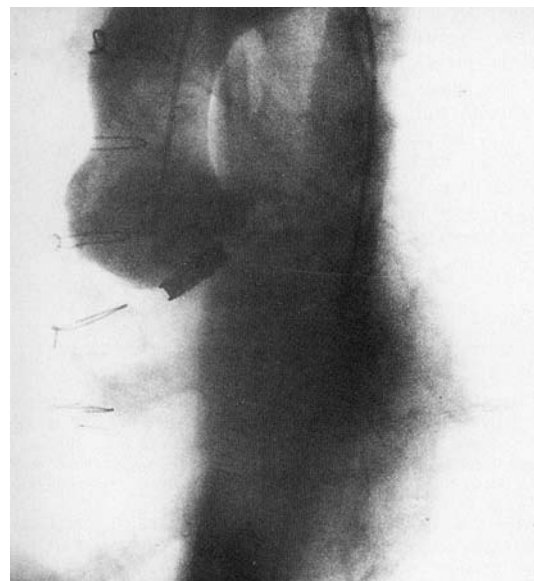


Figure 1. Aneurysm/circumscribed ectasia in the area of the sinus of Valsalva after use of an autologous pericardium patch

the development of aneurysms in the low-pressure-system, i.e. in the area of the right ventricular outflow tract. Different reports of such or comparable origins are summarized in Table I [10-13, 15-17].

The patient we are currently reporting on also received a pericardium patch in order to close a gap in the area of the aortic root that had occurred after the enlargement for aortic valve replacement many years before. The development of an aneurysm also occurred here, which had to be resected in the second re-do procedure in our institution.

The postoperative course shows that different complications can appear in the complexity of second (re-do) procedures and are not to be underestimated.

The alternatives to the pericardium or generally speaking to autologous material are controversially discussed in the current literature and firstly depend on the underlying disease.

Conclusions

Thus we draw the conclusion that autologous material should be used with a greater distance in the high-pressure system. Most citations of the literature show that the incidence of development of aneurysms under such circumstances is higher in comparison to other materials. That is why the use of synthetic agents, such as Dacron or PTFE, has to be discussed more intensively. In this context, however, as claimed by many other authors, the risk of postoperative infections comes to the fore [18, 19].

References

1. Szenpetery S, Cohen MD, Welch WJ, Bauerfeind RA, Ellenbogen KA. Pericardial repair of endocardial defect following regional endocardial resection for ventricular tachycardia. *J Card Surg* 1989; 4: 156-63.
2. Uusi A, Murase M, Maeda M, Tomita Y. Sandwich repair with two sheets of equine pericardial patch for acute posterior post-infarction ventricular septal defect. *Eur J Cardiothorac Surg* 1939 ; 7: 47-9.
3. Peniston C, Mahoney J, Panos A, Lichtenstein SV, Salerno TA. Myocardial aneurysm of the ascending thoracic aorta : Management with pericardial patch and bilateral muscle flaps. *J Thorac Cardiovasc Surg* 1989; 98: 308-10.
4. Elami A, Laks H, Milgater E, Sassoon AF. Use of a Dracon mesh coated pericardium for aortic augmentation. *J Card Surg* 1993; 8: 488-91.
5. Albes J, Haverich A, Freihorst J, von der Hardt H, Manthey-Stiers F. Management of myotic rupture of the ascending aorta after heart-lung-transplantation. *Ann Thorac Surg* 1990; 50: 982-3.
6. Seyold-Epting W, Chiariello L, Hallman GL, Cooley DA. Aneurysm of pericardial right ventricular outflow tract patches. *Thoraxchir Vask Chir* 1976; 24: 515-8.
7. Schlant C, Alexander W. *Hurst's The Heart* 1994; 8 th ed. Vol. II: pp. 2166 ff.
8. Blalock A, Taussig HB. Surgical treatment of malformations of the heart. *J Am Med Assoc* 1948; 128: 189-202.
9. Chiariello L, Meyer J, Wukasch DC, Hallman GL, Cooley DA. Intracardiac repair of tetralogy of Fallot. Five-year review of 403 patients. *J Thorac Cardiovasc Surg* 1997; 70: 529-35.
10. Butera G, Aggoun Y, Bonnet D, Bonhoeffer P. Aneurysmal dilation of a pericardial patch prepared with glutaraldehyde and used for closure of a ventricular septal defect. *Ital Heart J* 2001; 2: 317-8.
11. Bennink GB, Hitchcock FJ, Molenschot M, Hutter P, Sreeram N. Aneurysmal pericardial patch producing right ventricular inflow obstruction. *Ann Thorac Surg* 2001; 71: 1346-7.
12. Napoleone CP, Gabbieri D, Gargiulo G. Coarctation repair with proszhetic material: Surgical experience with aneurysm formation. *Ital Heart J* 2003; 4: 404-7.
13. Schoof PH, Hazekamp MG, van Ulzen K, Bartelings MM, Bruyn JA, Helbing W, et al. Autologous pericardium for ventricular septal defect closure. *J Heart Valve Dis* 1998; 7: 407-9.
14. Schulte HD, Bircks W, Frenzel H, Horstkotte D, Jungblut RM, Oubari M. Patch-graft enlargement of the aortic root using autologous pericardium – long term results. *Thorac Cardiovasc Surg* 1983; 31: 219-23.
15. Al-Hroob A, Husayni TS, Freter A, Chiemmongkoltip P, Ilbawi MN, Arcilla RA. Aortic aneurysm after patch aortoplasty for coarctation: analysis of patch size and wall growth. *Pediatr Cardiol* 2003; 24: 10-6
16. Bromberg BI, Beekman RH, Rocchini AP, Snider AR, Bank ER, Heidelberger K, et al. Aortic aneurysm after patch aortoplasty repair of coarctation: A prospective analysis of prevalence, screening tests and risks. *J Am Coll Cardiol* 1989; 14: 734-41.
17. Ala-Kulju K, Heikkinen L. Aneurysms after patch aortoplasty for coarctation of the aorta: Long-term results of surgical management. *Ann Thorac Surg* 1989; 47: 853-6.
18. Naylor AR, Payne D, London NJ, Thompson MM, Dennis MS, Sayers RD, Bell PR. Prosthetic patch infection after carotid endarterectomy. *Eur J Endovasc Surg* 2002; 23: 11-6.
19. Vas SI. Infections related to prosthetic materials in patients on chronic dialysis. *Clin Microbiol Infect* 2002; 8: 705-8.